

Original Article

Intraoperative frozen section evaluation of ureteral and urethral margins: studies of 203 consecutive radical cystoprostatectomy for men with bladder urothelial carcinoma

Haijun Zhou, Jae Y Ro, Luan D Truong, Alberto G Ayala, Steven S Shen

Department of Pathology and Genomic Medicine, Houston Methodist Hospital, Weill Medical College of Cornell University, Houston, TX, USA

Received June 9, 2014; Accepted June 25, 2014; Epub July 12, 2014; Published July 15, 2014

Abstract: Intraoperative frozen section (FS) evaluation of ureteral and urethral margins is frequently requested during radical cystoprostatectomy in patients with bladder urothelial carcinoma. However, it is still controversial whether intraoperative FSs of ureteral and urethral margins are necessary in all patients with cystoprostatectomy or a risk-based assessment with limited to the high risk patients is the best approach. A total of 203 radical cystoprostatectomy specimens with FS evaluation on margin status from men treated for bladder urothelial carcinoma from 2003 to 2010 in our institution were reviewed. Clinicopathologic features studied include: patients' age, pathologic tumor stage, presence of carcinoma in-situ (CIS), and intraoperative FS diagnosis. All 203 patients had intraoperative FS evaluation of ureter, and of these, 37 patients had additional urethra FS evaluation. Of the 203 ureteral FS cases, 17 (8.4%) had positive margin for CIS (16 cases) or CIS with invasive urothelial carcinoma (1 case). All 17 patients with positive ureteral margin on FS had concomitant CIS in the bladder (15.5%; 17 of 110 patients). In contrast, none of the patients without concomitant CIS (n=93) had positive ureteral margins on FS. Among 37 patients who also had FS evaluation on urethral resection margin, 3 patients (8.1%) had positive margins for CIS and all three of them had concomitant CIS in the bladder. Positive ureteral/urethral margin was not associated with patients' age or tumor stage, but was significantly associated with the presence of CIS in the bladder ($p < 0.001$). Our study demonstrates that presence of concomitant CIS in bladder cancer was often associated with positive ureteral or urethral margin for CIS or invasive carcinoma; therefore, intraoperative FS evaluation may be indicated to these patients with concomitant bladder CIS. In contrast, in patients with no associated concomitant CIS in the bladder, FS of ureteral/urethral margins may not be necessary unless other clinical justification is present.

Keywords: Intraoperative frozen section evaluation, margins, bladder cancer, carcinoma in situ

Introduction

Radical cystectomy or cystoprostatectomy with pelvic lymph node dissection is the standard procedure in male patients for the management of muscle-invasive bladder cancer or non-muscle-invasive cancers with high risk features such as a bulky mass, a superficial cancer that is resistant to intravesical therapy, or micropapillary histology [1, 2]. Intraoperative frozen section (FS) evaluation of the ureters has been recommended to reduce the risk of recurrence in the remaining ureters and assure a tumor-free anastomosis. However, the efficacy of

achieving a negative ureteral margin after cystectomy is still under debate since some studies have not proved that FS free negative margin confers a decreased subsequent upper tract recurrence or an improved long term survival [3-8]. Tumor recurrence rate at the uretero-intestinal anastomosis after radical cystoprostatectomy is very low (about 1%) and most patients will die of systemic disease rather than local recurrence [4, 9, 10]. Therefore, it is still controversial whether routine intraoperative FS evaluation of ureteral and urethral margins is necessary for all patients or for only a limited high-risk subgroup of patients.

Intraoperative frozen section evaluation of ureteral and urethral margins

Table 1. Summary of intraoperative frozen section diagnoses of ureter and urethra during radical cystoprostatectomy

	Ureter	Urethra
Total number of cases with FS*	203	37
Positive margin with CIS**	16	3
Positive margin with invasive carcinoma	1	0
Total positive margin cases	17	3

*FS - frozen section; **CIS - carcinoma in situ.

Table 2. Association of positive ureteral or urethral margins with presence of concomitant urothelial carcinoma in-situ

	Cases with positive ureteral margin	Cases with positive urethral margin
Bladder tumor with concomitant CIS (n=110)	17 (14.5%)*	3 (2.7%)**
Bladder tumor without concomitant CIS (n=93)	0 (0%)	0 (0%)

*P<0.001; **p=0.247.

In the current study, we present the Houston Methodist Hospital experience of utilization of intraoperative FS evaluation of ureter and urethra margins during radical cystoprostatectomy in men for bladder urothelial carcinoma and evaluate whether a risk-based approach is feasible.

Patients and methods

The study was conducted with an approval from the Institutional Review Board of The Houston Methodist Hospital (PAC IRB protocol 3-0155-04), and the pathology database from the Houston Methodist Hospital was reviewed. This study comprised 203 men with bladder urothelial carcinoma treated by radical cystoprostatectomy plus pelvic lymph node dissection with FS evaluation on margin status from 2003 to 2010. Nine cases of cystoprostatectomy without intraoperative FS evaluation were excluded from the study. Clinical history and pathology reports were reviewed. Clinicopathologic features studied include: patients' age, pathologic tumor stage, presence of carcinoma in-situ (CIS), and intraoperative FS diagnosis. Chi square test and logistic regression analysis were performed for statistical analysis.

Results

From 2003 to 2010, 203 patients underwent radical cystoprostatectomy for bladder urothelial carcinoma at our institution had intraoperative FS evaluation of ureteral and/or urethral

margins. The average age of patients in this series was 67.1 years (range 39.2 to 89.1). Primary tumor stage and percentage distribution of all the patient were as follows: pT0/Tx (17 cases; 8.4%), pTis or pTa (42 cases; 20.7%), pT1 (23 cases; 11.3%), pT2 (39 cases; 19.2%), pT3 (72 cases; 35.5%) and pT4 (10 cases; 4.9%).

Incidence of positive margins in bladder cancer patients underwent radical cystoprostatectomy

Of the 203 patients who had radical cystoprostatectomy and intraoperative FS evaluation, 17 (8.4%) cases had positive ureteral margins with urothelial CIS and one case of invasive urothelial carcinoma with CIS. In 37 patients who also had urethral FS evaluation, 3 patients (8.1%) had positive urethral margin for CIS (**Table 1**).

Association of positive urethral and urethral margins with presence of bladder urothelial CIS

In 203 bladder cancer patients underwent radical cystoprostatectomy, 110 patients had concomitant CIS in the bladder. Seventeen of 110 (15.5%) bladder cancer patients with CIS had positive FS ureteral margin. In contrast, in 93 patients without concomitant CIS, none of them had positive FS ureteral margin (**Table 2**). Similarly, all 3 patients with positive urethral margin had concomitant urothelial CIS in the bladder.

In this series, intraoperative FS diagnoses were accurate in determining positive margins. There were no false positive or false negative intraoperative FS diagnoses. Representative FS photomicrographs of ureteral margins with reactive change and positive margin, and positive urethral margin are shown in **Figure 1**.

Logistic regression analysis showed that positive ureteral margin was not associated with patients' age or tumor pathologic stage, but was significantly associated with the presence of CIS in the bladder (p<0.001).

Intraoperative frozen section evaluation of ureteral and urethral margins

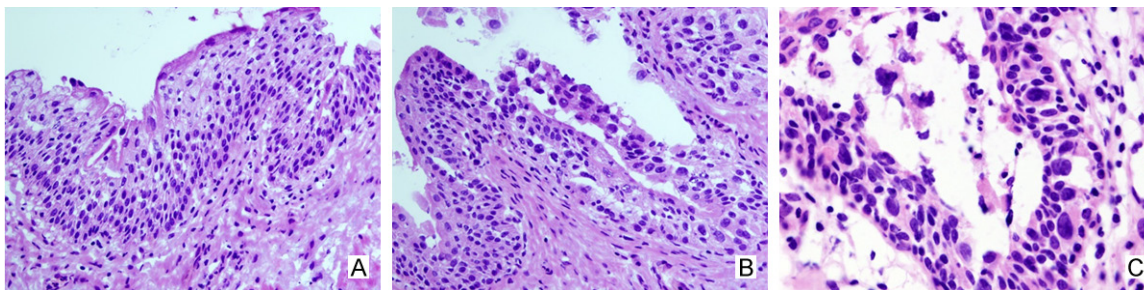


Figure 1. Frozen section evaluation of ureteral and urethral margins. A. Ureteral margin with normal urothelial cells showing mild reactive change (H&E 200x): there is presence of umbrella cells and preservation of cellular polarity. The cells are uniform with minimal cytologic atypia; B. Ureteral margin positive for urothelial carcinoma in situ (H&E 200x): In contrast to relatively normal urothelial cells on the left, the tumor cells on the right show significant nuclear enlargement, hyperchromasia, and loss of cellular polarity. C. Positive urethral margin for urothelial carcinoma in situ (H&E 400x): There are scattered large atypical tumor cells (pagetoid spread) in the background of normal urothelial cells.

Discussion

Our study focused on male bladder cancer patients who underwent radical cystoprostatectomy. In this study, we found a positive ureteral margin rate of 8.4% evaluated by intraoperative FS (**Table 2**). This finding is comparable to the 2%-10% positive margin reported by others [3-7, 11, 12]. The concomitant CIS of the bladder in our series accounts for 54.2% of all patients (110 of 203 cases), slightly lower than that (60%) of reported in the literature [4, 10, 13]. Our logistic regression analysis showed that positive ureteral/urethral margin was significantly associated with the presence of CIS in the bladder ($p < 0.001$), but not with patients' age or tumor stage.

The rationale to perform FS evaluation of the surgical margins at cystectomy is based on the concept of improved cancer control by achieving a tumor-free uretero-intestinal anastomosis and therefore prolonging cancer free survival. However, current data have not uniformly supported this conclusion [3-8]. The question still remains whether routine intraoperative FSs of ureteral and urethral margins are necessary for all patients.

Recent study series have shown the overall incidence of ureteric CIS is less than 8%, occurring most often in the distal ureter [3, 4, 7]. When the redundant ureter segment resected above the common iliac vessels is performed, CIS was detected in only 0.1% on permanent section [3]. The overall upper tract recurrence rate after radical cystectomy is reportedly 2.4%

to 6.6%, with most recurrences identified within the first 3 years after cystectomy (range 1.4-108 months) [9, 11, 14-21]. In particular, anastomotic recurrence rates are reported to be <1% which are exceedingly rare [3-8, 22]. There is no evidence so far that complete extirpation of malignant ureteric involvement proved by negative FS margin during radical cystectomy will eliminate the risk for recurrent upper tract tumor disease [3, 4, 7, 10, 21, 23, 24].

Ureteral CIS involvement is significantly associated with the presence of the CIS in bladder. It has been reported that 80-82% of patients with CIS in the ureter have CIS in the bladder [3, 13]. Raj et al reported 30% of patients with bladder CIS have ureteric involvement in the radical cystectomy specimen versus only 9% of patients without, and concluded that bladder CIS was a significant predictor of ureteric involvement on permanent section [4]. Tran et al and Solsona et al reported a significantly higher recurrence rate of upper ureteral tumors in patients with CIS of the bladder (16%-21.2%) vs. patients without (2.3%-5%) [13, 25]. Recurrent upper ureteral tumors happened in 17% of patients with CIS of the ureter at FS evaluation versus 3% in patients with negative FS evaluation [3]. Furthermore, Sanderson et al found patients with tumor involvement of the urethra are at highest risk for recurrent upper tract tumors [10]. Since our study and that of others demonstrating significant association of positive FS margins with CIS in the bladder, a risk-based approach for the application of the FS evaluation seems to be reasonable to propose.

Intraoperative frozen section evaluation of ureteral and urethral margins

It is arguable that performing an intraoperative ureteral FS evaluation is necessary in all patients who undergo radical cystectomy since risk of upper urinary tract recurrence is low [4, 6, 7, 17]. It does not achieve a favorable cost-benefit ratio either. One study has reported that the cost to pick up one patient with CIS or solid urothelial carcinoma of the ureter on FS was \$6,471 [26]. Therefore, performing FS for all patients seems to be not cost-effective. For the evidence based medical practice, a risk-based approach for the application of the FS evaluation is further warranted.

In summary, in this study we have found that the rate of positive ureteral margin as evaluated by FS is 8.0% in consecutive bladder cancer patients undergoing radical cystoprostatectomy. The presence of concomitant CIS in patient with bladder cancer is highly associated with positive ureteral and urethral margins. Therefore, intraoperative FS is helpful for this group of patients. However, in patients without history of CIS, routine intraoperative FS of ureteral margin may not be indicated.

Disclosure of conflict of interest

None.

Address correspondence to: Dr. Steven S Shen, Department of Pathology and Genomic Medicine, Houston Methodist Hospital and Weill Medical College of Cornell University, 6565 Fannin Street, M227, Houston, TX 77030, USA. Tel: 713-441-6987; Fax: 713-793-1603; E-mail: stevenshen@houston-methodist.org

References

- [1] Stein JP, Skinner D. Radical cystectomy for invasive bladder cancer: long-term results of a standard procedure. *World J Urol* 2006; 24: 296-304.
- [2] Nagele U, Anastasiadis AG, Merseburger AS, Corvin S, Hennenlotter J, Adam M, Sievert KD, Stenzl A, Kuczyk MA. The rationale for radical cystectomy as primary therapy for T4 bladder cancer. *World J Urol* 2007; 25: 401-5.
- [3] Schumacher MC, Scholz M, Weise ES, Fleischmann A, Thalmann GN, Studer UE. Is there an indication for frozen section examination of the ureteral margins during cystectomy for transitional cell carcinoma of the bladder? *J Urol* 2006; 176: 2409-13.
- [4] Raj GV, Tal R, Vickers A, Bochner BH, Serio A, Donat SM, Herr H, Olgac S, Dalbagni G. Significance of intraoperative ureteral evaluation at radical cystectomy for urothelial cancer. *Cancer* 2006; 107: 2167-72.
- [5] Johnson DE, Wishnow KI, Tenney D. Are frozen-section examinations of ureteral margins required for all patients undergoing radical cystectomy for bladder cancer? *Urology* 1989; 33: 451-4.
- [6] Schoenberg MP, Carter HB, Epstein JI. Ureteral frozen section analysis during cystectomy: a reassessment. *J Urol* 1996; 155: 1218-20.
- [7] Silver DA, Stroumbakis N, Russo P, Fair WR, Herr HW. Ureteral carcinoma in situ at radical cystectomy: does the margin matter? *J Urol* 1997; 158: 768-71.
- [8] Lee SE, Byun SS, Hong SK, Chang IH, Kim YJ, Gill MC, Song SH, Kim KT. Significance of cancer involvement at the ureteral margin detected on routine frozen section analysis during radical cystectomy. *Urol Int* 2006; 77: 13-7.
- [9] Balaji KC, McGuire M, Grotas J, Grimaldi G, Russo P. Upper tract recurrences following radical cystectomy: an analysis of prognostic factors, recurrence pattern and stage at presentation. *J Urol* 1999; 162: 1603-6.
- [10] Sanderson KM, Cai J, Miranda G, Skinner DG, Stein JP. Upper tract urothelial recurrence following radical cystectomy for transitional cell carcinoma of the bladder: an analysis of 1,069 patients with 10-year followup. *J Urol* 2007; 177: 2088-94.
- [11] Malkowicz SB, Skinner DG. Development of upper tract carcinoma after cystectomy for bladder carcinoma. *Urology* 1990; 36: 20-2.
- [12] Batista JE, Palou J, Iglesias J, Sanchotene E, da Luz P, Algaba F, Villavicencio H. Significance of ureteral carcinoma in situ in specimens of cystectomy. *Eur Urol* 1994; 25: 313-5.
- [13] Tran W, Serio AM, Raj GV, Dalbagni G, Vickers AJ, Bochner BH, Herr H, Donat SM. Longitudinal risk of upper tract recurrence following radical cystectomy for urothelial cancer and the potential implications for long-term surveillance. *J Urol* 2008; 179: 96-100.
- [14] Donat SM. Staged based directed surveillance of invasive bladder cancer following radical cystectomy: valuable and effective? *World J Urol* 2006; 24: 557-64.
- [15] Zincke H, Garbeff PJ, Beahrs JR. Upper urinary tract transitional cell cancer after radical cystectomy for bladder cancer. *J Urol* 1984; 131: 50-2.
- [16] Hastie KJ, Hamdy FC, Collins MC, Williams JL. Upper tract tumours following cystectomy for bladder cancer. Is routine intravenous urography worthwhile? *Br J Urol* 1991; 67: 29-31.
- [17] Kenworthy P, Tanguay S, Dinney CP. The risk of upper tract recurrence following cystectomy in patients with transitional cell carcinoma involving the distal ureter. *J Urol* 1996; 155: 501-3.

Intraoperative frozen section evaluation of ureteral and urethral margins

- [18] Tsuji Y, Nakamura H, Ariyoshi A. Upper urinary tract involvement after cystectomy and ileal conduit diversion for primary bladder carcinoma. *Eur Urol* 1996; 29: 216-20.
- [19] Huguet-Pérez J, Palou J, Millán-Rodríguez F, Salvador-Bayarri J, Villavicencio-Mavrich H, Vicente-Rodríguez J. Upper tract transitional cell carcinoma following cystectomy for bladder cancer. *Eur Urol* 2001; 40: 318-23.
- [20] Stenzl A, Bartsch G, Rogatsch H. The remnant urothelium after reconstructive bladder surgery. *Eur Urol* 2002; 41: 124-31.
- [21] Sved PD, Gomez P, Nieder AM, Manoharan M, Kim SS, Soloway MS. Upper tract tumour after radical cystectomy for transitional cell carcinoma of the bladder: incidence and risk factors. *BJU Int* 2004; 94: 785-9.
- [22] Sharma TC, Melamed MR, Whitmore WF Jr. Carcinoma in-situ of the ureter in patients with bladder carcinoma treated by cystectomy. *Cancer* 1970; 26: 583-7.
- [23] Herr HW, Whitmore WF Jr. Ureteral carcinoma in situ after successful intravesical therapy for superficial bladder tumors: incidence, possible pathogenesis and management. *J Urol* 1987; 138: 292-4.
- [24] Schumacher MC, Studer UE. Ureteric frozen sections during radical cystectomy for transitional cell carcinoma of the bladder—to do or not to do? *BJU Int* 2009; 103: 1149-50.
- [25] Solsona E, Iborra I, Rubio J, Casanova J, Dumont R, Monrós JL. Late oncological occurrences following radical cystectomy in patients with bladder cancer. *Eur Urol* 2003; 43: 489-94.
- [26] Touma N, Izawa JI, Abdelhady M, Moussa M, Chin JL. Ureteral frozen sections at the time of radical cystectomy: reliability and clinical implications. *Can Urol Assoc J* 2010; 4: 28-32.